

BRONCHO-PULMONARY NEUROENDOCRINE TUMORS

Introduction

- Clinical evaluation, including an assessment of the performance status PS.
- Pathology review.
- General laboratory tests:
 - Complete Blood Count (CBC),
 - Chemistry profile.
- Serum markers:
 - Beneficial in diagnosis and surveillance.
- Test for probable association with Multiple Endocrine Neoplasia (MEN1)
- 5-hydroxyindoleacetic acid (5-HIAA) and Chromogranin A.
- Adrenocorticotrophic hormone (ACTH) and cortisol for Cushing's syndrome as would be clinically indicated.
- Imaging diagnostics
 - CT scan chest.
 - MRI abdomen or multiphasic CT scan abdomen (plain, arterial, venous & delayed).
 - Somatostatin receptor-based imaging, Gallium 68 dotatate, PET/CT (preferred) or somatostatin receptor.
 - Echocardiogram: if carcinoid syndrome is present.

TNM Staging

T – Primary Tumor

TX	Primary tumor cannot be assessed
T0	No evidence of primary tumor
Tis	Carcinoma in situ
T1	Tumor ≤ 3cm surrounded by lung or visceral pleura without bronchoscopic evidence of invasion.
T1im	Minimally invasive adenocarcinoma (≤3 cm in greatest dimension) with predominantly lepidic pattern ≤ 5mm invasion.
T1a	Tumor ≤ 1cm
T1b	Tumor > 1but ≤ 2cm
T1c	Tumor > 2 cm but ≤ 3 cm
T2	Tumor > 3 cm but ≤ 5 cm or having any of the following features:

	Involves the main bronchus regardless of the distance to the carina, but without the involvement of the carina, Involve the visceral pleura, Associated with atelectasis or obstructive pneumonitis that extend to the hilar region.
T2a	Tumor > 3 cm but ≤ 4 cm
T2b	Tumor > 4 cm but ≤ 5 cm
T3	Tumor > 5 cm but ≤ 7 cm or directly invading any of the following: parietal pleura, chest wall, phrenic nerve, parietal pericardium, or separate tumor nodule(s) in the same lobe as the primary.
T4	Tumor > 7 cm or the tumor of any size invading one or more of the following: Diaphragm, mediastinum, heart, great vessels, trachea, recurrent laryngeal nerve, esophagus, vertebral body, carina, separate tumor nodule(s) in an ipsilateral lobe different from the primary.

N – Regional Lymph Nodes

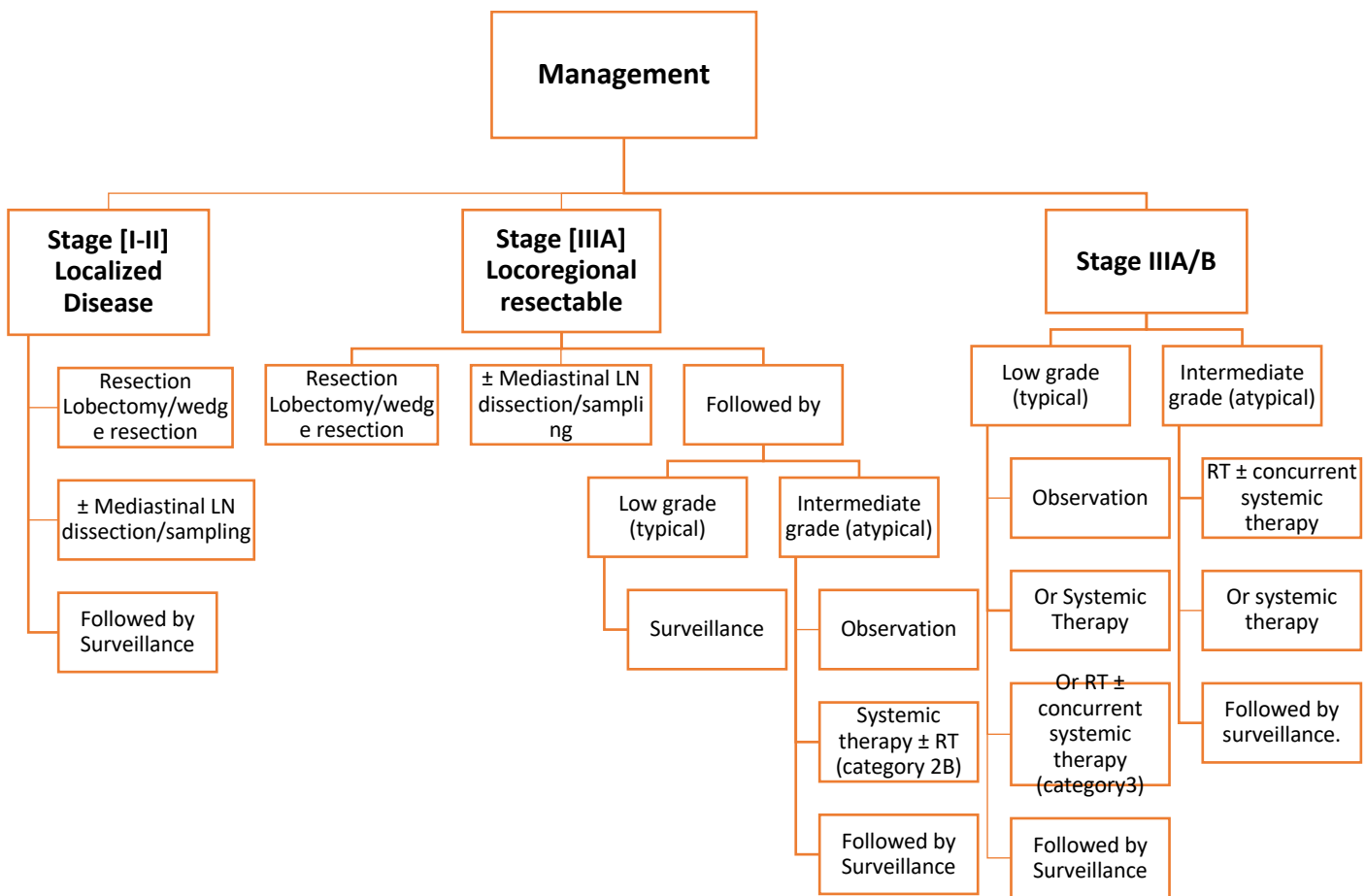
NX	Regional LN cannot be assessed.
N0	No regional LN metastasis.
N1	Metastasis in ipsilateral peribronchial and/or ipsilateral hilar LNs and intrapulmonary nodes, including involvement by direct extension.
N2	Metastasis in ipsilateral mediastinal and/or subcarinal LNs.
N3	Metastasis in contralateral mediastinal, contralateral hilar, ipsilateral or contralateral scalene, or supraclavicular LNs.

M – Distant Metastasis

M0	No distance metastasis
M1	Distance metastasis
M1a	Separate tumor nodule(s) in a contralateral lobe, tumor with pleural or pericardial nodules or malignant pleural or pericardial effusion.
M1b	Single extrathoracic metastasis in a single organ (including involvement of non-regional LN)
M1c	Multiple extrathoracic metastases in a single organ or in multiple organs.

Cancer Stage Grouping			
Occult	Tx	N0	M0
Stage 0	Tis	N0	M0
Stage IA1	T1im, T1a	N0	M0
Stage IA2	T1b	N0	M0
Stage IA3	T1c	N0	M0
Stage IB	T2a	N0	M0
Stage IIA	T2b	N0	M0
Stage IIB	T1a,T1b,T1c	N1	M0
	T2aT2b	N1	M0
	T3	N1	M0
Stage IIIA	T1a,T1b,T1c	N1	M0
	T2aT2b	N1	M0
	T3	N1	M0
	T4	N0, N1	M0
Stage IIIB	T1a,T1b,T1c	N3	M0
	T2aT2b	N3	M0
	T3	N2	M0
	T4	N2	M0
Stage IIIC	T3	N3	M0
	T4	N3	M0
Stage IVA	Any T	Any N	M1a
	Any T	Any N	M1b
Stage IVB	Any T	Any N	M1c

Management



Metastatic disease (Stage IV)

Asymptomatic, low grade and low tumor burden (typical)

Observation or
 Octreotide or Lanreotide (if somatostatin receptor-positive imaging and/or hormonal symptoms).

Clinically significant tumor burden and low grade (typical) or evidence of progression

If asymptomatic:
 Observation

If somatostatin receptor-positive imaging and/or hormonal symptoms:
 Octreotide or Lanreotide

If somatostatin receptor-positive imaging and progression on octreotide/lanreotide:
 Everolimus or
 Peptide receptor radionuclide therapy (PRRT) with lutetium Lu dotatate

N.B. Consider changing therapy if progression on first-line therapy.

Intermediate grade (atypical)

Observation for selected patients

If somatostatin receptor-positive imaging and/or hormonal symptoms:

Octreotide or Lanreotide

If somatostatin receptor-positive imaging and progression on octreotide/lanreotide:

Everolimus or

Peptide receptor radionuclide therapy (PRRT) or

Chemotherapy (for selected patients).

N.B. Consider changing therapy if progression on first-line therapy.

Multiple lung nodules or diffuse idiopathic pulmonary neuroendocrine cell hyperplasia (DIPNECH)

Observation or

If somatostatin receptor-positive imaging and/or hormonal symptoms:

Octreotide or Lanreotide

Sandostatin LAR:

Dose: 30mg IM injection every four weeks.

The dose can be increased if no symptom control

Short-acting octreotide can be subcutaneous injections to cover the first two weeks after LAR octreotide until its action start or to control breakthrough carcinoid syndrome.

Cisplatin + Etoposide: As in SCLC protocol.

Follow up

- History, clinical examination, routine labs, markers (see below), CT scan, and multiphasic CT abdomen:
 - Every three months for one year,
 - Then every 12-24 months for ten years.
- Chromogranin A (category 3) level may be misleading as it could be elevated with:
 - Hepatic or renal impairment,
 - The use of proton pump inhibitors.
- 5-HIAA: 24-hour urine or plasma

N.B. The patient should stop the following items for 48 hours before collecting urine:
Avocado, banana, cantaloupe, eggplant, pineapple, plums, hickory nuts, plantains, kiwi, grapefruit, honeydew, dates, walnuts, coffee, alcohol, smoking, acetaminophen, ephedrine, diazepam, glyceryl guaiacolate (in cough mixtures) and phenobarbital.
- Gallium 68 scan as indicated by clinical assessment and/or suggested by nuclear medicine staff.

The spectrum of pulmonary neuroendocrine tumors/neoplasm (NET/NEN)

NET	WHO grade	Histology	Mitoses per 2 mm²	Presence of Necrosis
Low grade Well-differentiated	I	Typical carcinoid	<2	None
Intermediate grade Well differentiated	II	Atypical carcinoid	2 – 10	Present
High grade Poorly differentiated	III	Large cell NET	> 10	Extensive
		Small cell lung cancer		High

An Algorithmic Overview for the Investigation and Treatment of Pulmonary NENs (NETs)

