

GU / GY CANCERS AND OTHER RARE MALIGNANCIES UNIT

Members:

Dr. Ehab Abdou	Consultant
Dr. Mohamed Ashour	Senior Specialist
Dr. Eman Moghazy	Senior Registrar
Dr. Shereen Ahmed	Registrar
Dr. Mohamed El Khateeb	Registrar

EPITHELIAL OVARIAN CANCER

Initial Workup

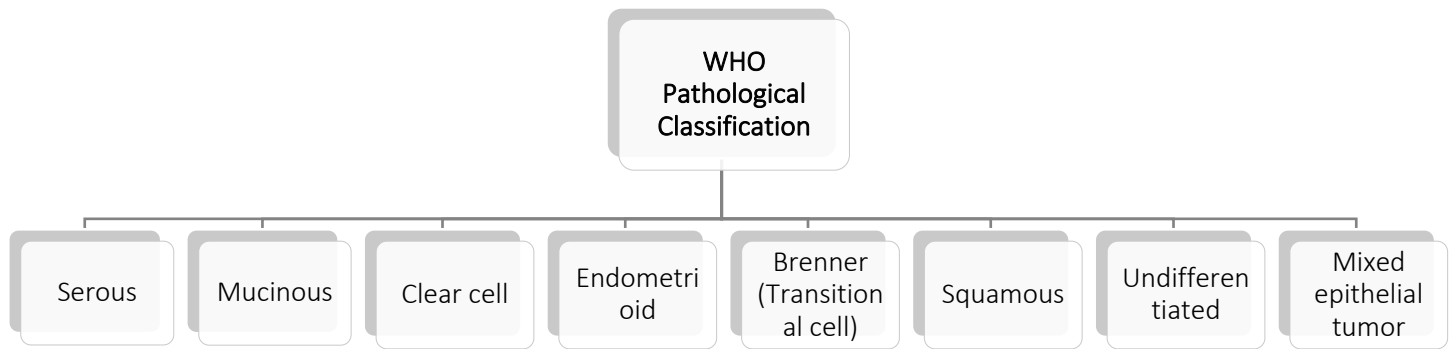
- Clinical examination:
 - Performance status and
 - Gynecological examination
- Pathology review
- Laboratory investigations:
 - Complete blood count (CBC)
 - Chemistry profile,
 - Serum CA125
- Chest X-ray
- Computed tomography (CT) scan of the abdomen and pelvis.
- The routine use of positron emission tomography (PET) with 18F-labeled fluoro-2-deoxyglucose (FDG)/CT scan for initial staging is not recommended.

Tissue Diagnosis:

- The definitive diagnosis of epithelial ovarian cancer requires a tissue diagnosis.
 - Surgically:
 - Laparoscopic approach or
 - Through a metastatic lesion.
 - Ascitic fluid:
 - In some cases, adenocarcinoma cytology of ascitic fluid supplements:
 - Clinical impression,
 - High level of CA 125, and
 - CT scan findings
 - These data may be enough to consider the diagnosis and proceed to treat.

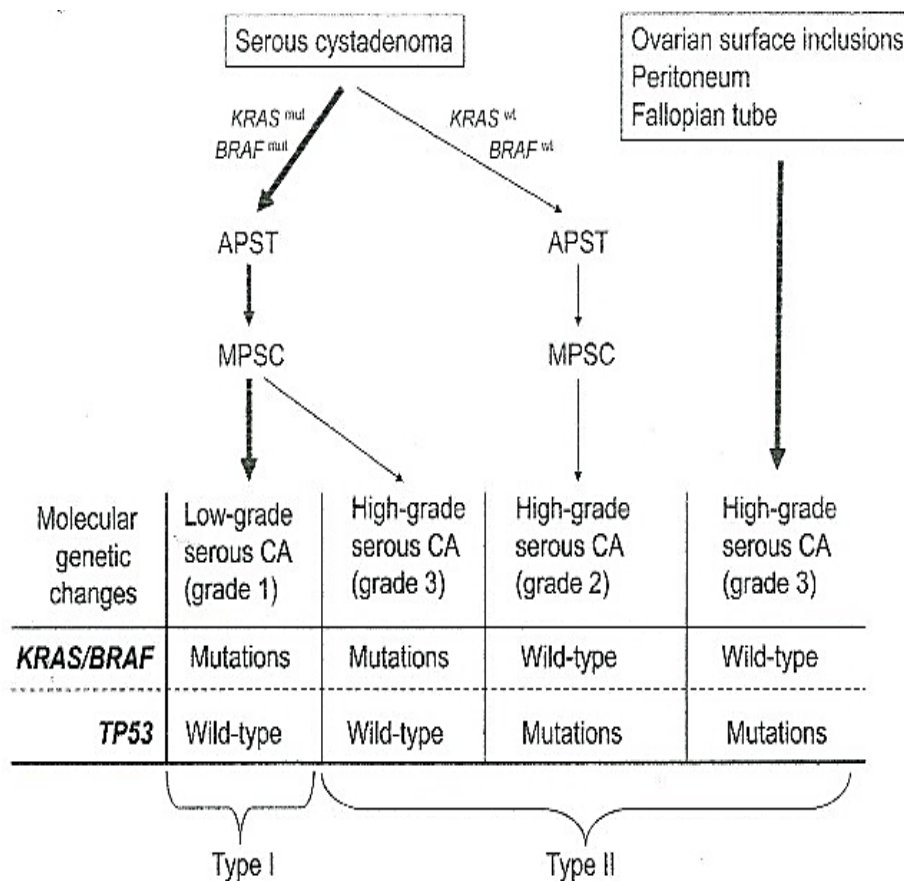
Pathological diagnosis should be made according to the World Health Organization (WHO) classification. Ovarian cancer is no more considered as one disease.

WHO Pathological Classification



Biologically, Ovarian Cancer is classified into types (I and II) based on:

- Tumor grade
- Origin
- Mutational changes



FIGO Staging (Fédération Internationale de Gynécologie et d'Obstétrique)

Stage I	Limited to ovaries
IA	One ovary
IB	Both ovaries
IC	Ruptured capsule, surface tumor or positive washing
Stage II	Tumor involves one or both ovaries with pelvic extension
IIA	Pelvic extension
IIB	Other pelvic tissue
IIC	Positive washings, ascites
Stage III	Abdominal extension and/or regional lymph nodes
IIIA	Microscopic peritoneal metastases
IIIB	Macroscopic peritoneal metastases ≤ 2 cm
IIIC	Macroscopic peritoneal metastases > 2 cm and/or regional lymph nodes
Stage IV	Distant metastases outside the peritoneal cavity

Treatment of Invasive Epithelial Ovarian Cancer

FIGO Stage I

1) Surgery

- Surgery should involve:
 - Total abdominal hysterectomy,
 - Bilateral salpingo-oophorectomy,
 - Omentectomy,
 - Random peritoneal biopsies including para-colic gutters
 - At least pelvic and para-aortic lymph node sampling.
- Comprehensive staging and unilateral salpingo-oophorectomy may not be associated with a high risk of recurrence in younger patients with:
 - Localized, unilateral tumors (stage I) and
 - The desire of fertility and
 - Favorable histology:
 - Mucinous, serous, endometrioid or
 - Mixed histology grade I or grade II

N.B. Wedge biopsy of the contralateral ovary should be performed, if the contralateral ovary is not normal on inspection.

- Surgery alone may be adequate in:
 - Well-differentiated tumors
 - Non-clear cell histology (grade 1 stage IA and B)

Special Consideration:

- FIGO stage I tumors with dense adhesions to pelvic structures have a similar relapse rate as FIGO II.
- These patients should be 'upstaged' and treated as FIGO II tumors.

2) Adjuvant Chemotherapy

- Adjuvant chemotherapy is indicated in:
 - Stage IB: Poorly differentiated tumors (grades 2 and 3).
 - Stage IC
 - Any grade 3
 - Clear cell histology.

FIGO Stage II–IIIC

1) Surgery

- Optimal cytoreduction (total macroscopic tumor clearance)
 - The goal of no residual disease should be undertaken.
 - A residual < 1 cm associated with better survival.

N.B.

- Value of pelvic and para-aortic lymphadenectomy in advanced disease is still controversial.
- Role of secondary interval debulking surgery after primary surgery with suboptimal cytoreduction and three cycles of chemotherapy is not clear.
- Neoadjuvant Chemotherapy
- This is the standard of care for patients with extensive tumor dissemination (IIIC and IV) at presentation.
- Surgery may be non-feasible or would be incomplete.
- The majority of these patients will receive:
 - Three cycles of neoadjuvant chemotherapy,
 - Then assessment for the feasibility of surgical treatment
 - Followed by three more cycles.
- However, some patients may need to receive six cycles up-front to be enough to render them as surgical candidates.

3) Chemotherapy: Adjuvant and Neoadjuvant

- Adjuvant chemotherapy is offered as the following regimens.

Carboplatin + Paclitaxel

It is the recommended standard chemotherapy for advanced ovarian carcinoma (IIB –IIIC)

Carboplatin AUC 6 with Paclitaxel 175 mg/m²/3h every 3 weeks for six cycles.

N.B. AUC: area under the free carboplatin plasma concentration versus time curve.

Carboplatin + Docetaxel

Docetaxel 75 mg/m² is equally effective as for Paclitaxel but differ in toxicity profile.

It may be offered at the initial treatment plan for certain cases as those who have severe diabetic peripheral neuropathy.

Bevacizumab + Chemotherapy

Bevacizumab can be added for poor prognostic features (suboptimal surgery, stage IV), with the chemotherapy

It then can be continued for 12 to 15 months at a dose of 15 mg/kg every three weeks as long as there is no contraindication or toxicity.

Duration of Bevacizumab is not yet settled.

FIGO Stage IV

- Preoperative assessment is mandatory before proceeding in this management plan.
- The aim is maximal surgical cytoreduction at initial laparotomy as feasible.
- Patients could be considered for surgery as outlined for FIGO stage IIA–III disease in:
 - Younger patients with good performance status,
 - Pleural effusion as the only site of disease outside the abdominal cavity,
 - Small volume metastases and
 - No major organ dysfunction.
- If surgery is not planned:
 - Diagnosis should be confirmed by biopsy (laparoscopic approach may be needed) and
 - Chemotherapy administered as recommended for FIGO stage IIA – IIIC disease.

Response Evaluation

- Clinical assessment especially if the patient presented initially with:
 - Bulky palpable disease,
 - Ascites or
 - Pleural effusion.
- Serum CA125 should be measured:

- At intervals during chemotherapy or
- While on follow-up as long as it would seem to be contributory.
- CT scan chest, abdomen, and pelvis as indicated:
 - At baseline.
 - An interim CT scan after three cycles of chemotherapy
 - After six cycles of chemotherapy.
 - Evidence of relapse or unresponsiveness.

Follow Up

- History, physical examination including pelvic examination:
 - Every 3 months for 2 years,
 - Every 4 months during the third year and
 - Every 6 months during years 4 and 5 or until progression is documented.
- CA125 may accurately predict tumor relapse, as far as it was contributory at first diagnosis.
- CT scans should be performed if there is:
 - Clinical (symptomatic evidence of relapse during follow up) or
 - CA125 evidence of progressive disease.
- FDG PET/CT scans may be superior to CT scans in detecting small volume operable relapses for certain patients.

Recurrent Disease

Platinum-Sensitive

Definition

- Patients with long intervals (6-12 months) from initial chemotherapy.

Management

- These patients should be re-challenged with the same platinum-based combination chemotherapy or as will be otherwise indicated.
- Bevacizumab in combination with chemotherapy is another option for platinum-sensitive patients.

Platinum-Resistant or Refractory

Definition

- Patients with short treatment-free intervals (within 6 months) or
- having a resistant or refractory disease (if relapsed while on treatment)

Management

- These patients should receive another line of palliative chemotherapy that was not previously given.
- These include:
 - Docetaxel;
 - Gemcitabine;
 - Topotecan.

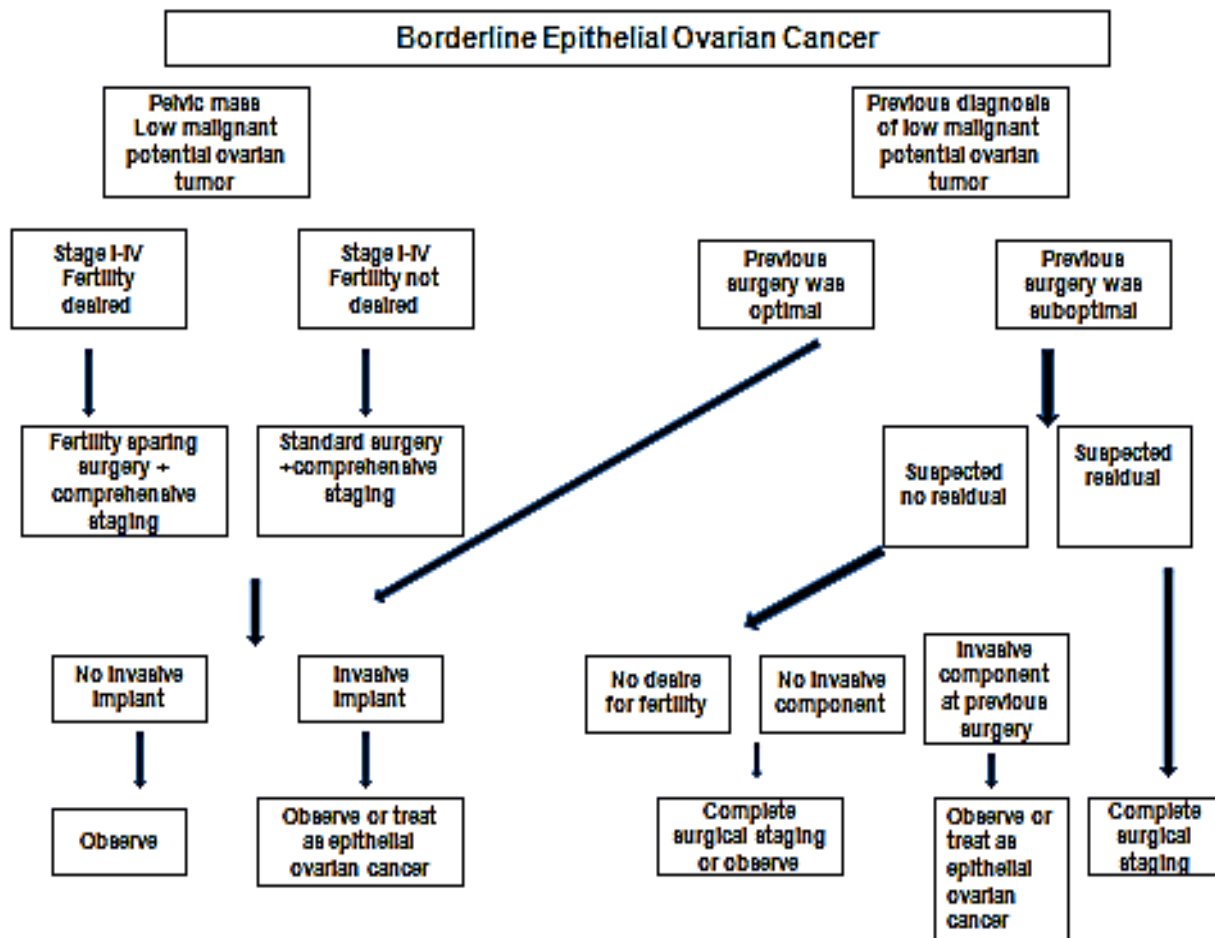
PARP-inhibitor maintenance treatment:**Niraparib, Rucaparib or Olaparib**

- Could be considered as maintenance monotherapy in BRCA mutated advanced ovarian cancer that has been treated with two or more lines of chemotherapy
 - Olaparib: phase 3 trial (SOLO2/ENGOT-Ov21)
 - Rucaparib: phase 2 trial (ARIEL2)
 - Niraparib: phase 3 trial (NOVA)

Hormonal Therapy:**Aromatase Inhibitors, Leuprolide, and Tamoxifen**

- Considered hormone recurrence therapy.

Borderline Epithelial Ovarian Cancer Management



References

- 1) Bristow RE, et al. Survival effect of maximal cytoreductive surgery for advanced ovarian carcinoma during the platinum era: a meta-analysis. *J Clin Oncol* 2002;20(5):1248-1259.
- 2) Goonewardene TI, et al. Management of asymptomatic patients on follow-up for ovarian cancer with rising CA-125 concentrations. *Lancet Oncol.* 2007;8(9):813-821.
- 3) Gordon AN, et al. Long-term survival advantage for women treated with pegylated liposomal doxorubicin compared with topotecan in phase 3 randomized study of recurrent and refractory epithelial ovarian cancer. *Gynecol Oncol.* 2004;95(1):1-8.