

GASTROENTEROPANCREATIC NEUROENDOCRINE TUMORS

Initial Workup

- Imaging Workup:
 - Multiphase CT scan chest + abdomen + pelvis
 - MRI if clinically indicated
 - Octreotide scan or Ga68-DOTA-TOC/NOC/-TATE PET scan (preferable) as a standard procedure.
 - FDG-PET scan is not a standard but may be useful in high-grade tumors or in doubtful cases.
 - Echocardiography in functioning intestinal NETs or liver metastases.
- Endoscopy (UGIE, colonoscopy) is not mandatory but is often of additional value.
- Laboratory workup:
 - Plasma chromogranin A (CgA)
 - Urine 5-HIAA.
 - Plasma neuron-specific enolase (NSE) may be useful in high-grade tumors or doubtful cases.
- Histological diagnosis is mandatory:
 - Gastroenteropancreatic (GEP) NETs share a common phenotype with immunoreactivity for pan-neuroendocrine markers: chromogranin A and synaptophysin.
 - NSE and CD56 may be helpful in some cases but are not specific for GEP-NETs.
 - Second pathology opinion is mandatory.
 - Histopathology report must include IHC for:
 - Chromogranin A (CgA),
 - Synaptophysin, and
 - KI67.

TNM classification for gastric endocrine tumors (European Neuroendocrine Tumor Society):

Tumor	
Tx	Primary tumor cannot be assessed
T0	No evidence of primary tumor
Tis	<i>In situ</i> tumor/dysplasia (< 0.5 mm)
T1	Tumor invades lamina propria or submucosa and ≤1 cm
T2	Tumor invades muscularis propria or submucosa and >1 cm
T3	Tumor penetrates serosa
T4	Tumor invades adjacent structures For any T, add (m) for multiple tumors

Node Status

Nx	Regional lymph nodes cannot be assessed
N0	No regional lymph node metastases
N1	Regional lymph node metastases

Metastasis

Mx	Distant metastases cannot be assessed
M0	No distant metastases
M1	Distant metastasis present

**TNM classification for endocrine tumors of the duodenum/ampulla proximal jejunum
(European Neuroendocrine Tumor Society)**
Tumor

Tx	Primary tumor cannot be assessed
T0	No evidence of primary tumor
T1	Tumor invades lamina propria or submucosa and has a size ≤ 1 cm
T2	Tumor invades muscularis propria or >1 cm
T3	Tumor invades pancreas or retroperitoneum
T4	Tumor invades peritoneum or other organs For any T, add (m) for multiple tumors

Node Status

Nx	Regional lymph nodes cannot be assessed
N0	No regional lymph node metastases
N1	Regional lymph node metastases

Metastasis

Mx	Distant metastases cannot be assessed
M0	No distant metastases
M1	Distant metastasis present

TNM classification for endocrine tumors of the pancreas (European Neuroendocrine Tumor Society)

Tumor	
Tx	Primary tumor cannot be assessed
T0	No evidence of primary tumor
T1	Tumor limited to the pancreas and size ≤ 2 cm
T2	Tumor limited to the pancreas and size 2-4 cm
T3	Tumor limited to the pancreas and size > 4 cm or invading duodenum or bile duct
T4	Tumor invading adjacent organs (stomach, spleen, colon, and adrenal gland) or the wall of large vessels (celiac axis or superior mesenteric artery) For any T, add (m) for multiple tumors

Node Status	
Nx	Regional lymph nodes cannot be assessed
N0	No regional lymph node metastases
N1	Regional lymph node metastases

Metastasis	
Mx	Distant metastases cannot be assessed
M0	No distant metastases
M1	Distant metastasis present

TNM classification for endocrine tumors of lower jejunum and ileum (European Neuroendocrine Tumor Society)

Tumor	
Tx	Primary tumor cannot be assessed
T0	No evidence of primary tumor
T1	Tumor invades mucosa or submucosa and has a size ≤ 1 cm
T2	Tumor invades muscularis propria or size > 1 cm
T3	Tumor invades subserosa
T4	Tumor invades peritoneum/other organs (celiac axis or superior mesenteric artery) For any T, add (m) for multiple tumors

Node Status	
Nx	Regional lymph nodes cannot be assessed
N0	No regional lymph node metastases
N1	Regional lymph node metastases

Metastasis	
Mx	Distant metastases cannot be assessed
M0	No distant metastases
M1	Distant metastasis present

TNM classification for endocrine tumors of colon and rectum (European Neuroendocrine Tumor Society)

Tumor	
Tx	Primary tumor cannot be assessed
T0	No evidence of primary tumor
T1	Tumor invades mucosa or submucosa
T1a	Size ≤ 1 cm
T1b	Size 1 – 2 cm
T2	Tumor invades muscularis propria or size > 2 cm
T3	Tumor invades subserosa, pericolic, and perirectal fat
T4	Tumor directly invades other organs/structures and/or perforates visceral peritoneum. For any T, add (m) for multiple tumors

Node Status	
Nx	Regional lymph nodes cannot be assessed
N0	No regional lymph node metastases
N1	Regional lymph node metastases

Metastasis	
Mx	Distant metastases cannot be assessed
M0	No distant metastases
M1	Distant metastasis present

Classifications

Classifications may slightly vary according to the guidelines (WHO, NCCN, ENETS).

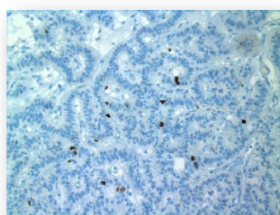
WHO Classification 2010

Neuroendocrine Neoplasms (NENs) of the Gastroenteropancreatic (GEP) System

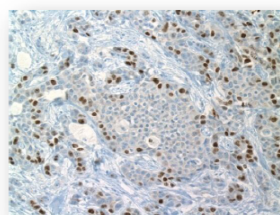
WHO 1980	WHO 2000	WHO 2010
I. Carcinoid	1. Well-differentiated endocrine tumor (WDET)* 2. Well-differentiated endocrine carcinoma (WDEC)* 3. Poorly differentiated endocrine carcinoma/small-cell carcinoma (PDEC)	1. NET G1 (carcinoid) 2. NET G2* 3. NEC G3 large-cell or small-cell type
II. Mucocarcinoid III. Mixed forms carcinoid-adenocarcinoma	4. Mixed exocrine-endocrine carcinoma (MEEC)	4. Mixed adenoneuroendocrine carcinoma (MANEC)
IV. Pseudotumor lesions	5. Tumor-like lesions (TLL)	5. Hyperplastic and preneoplastic lesions
NET, neuroendocrine tumor–well differentiated; NEC, neuroendocrine carcinoma–poorly differentiated; G, Grade		
*If the Ki67 index exceeds 20%, this NET may be labeled G3.		

Bosman FT, et al. WHO Classification of Tumours of the Digestive System. Lyon, France: IARC Press; 2010.

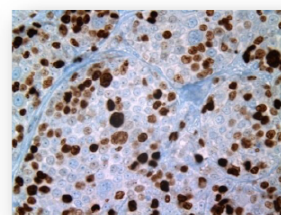
Grading of GEP-NENs According to ENETS



G1



G2



G3

Ki67 index	<2	2–20	>20
	(% of positive cells per 100 counted cells [§])		

Mitotic count	<2	2–20	>20
	(10 HPF)		

[§]Personal recommendation.

Mixed AdenoNeuroendocrine Carcinoma (MANEC)

- MANECs have two components which should be graded:
 - Neuroendocrine and
 - Exocrine

Both are recognizable as adenocarcinoma and neuroendocrine carcinoma in one lesion.
- However, each component must represent at least 30% of all neoplastic cells, to be labeled as mixed adenoneuroendocrine tumor (MANET).
- The identification of scattered neuroendocrine cells (< 30%) in adenocarcinomas does not qualify for MANEC.

WHO 2017 Classification of Pancreatic NETs

World Health Organization Classification 2017 for Pancreatic Neuroendocrine Neoplasms

Well differentiated NENs	Ki67index*	Mitotic index
Neuroendocrine tumour (NET) G1	<3 %	<2/10 HPF
Neuroendocrine tumour (NET) G2	3-20 %	2-20/10 HPF
Neuroendocrine tumour (NET) G3	>20 %	>20/10 HPF
Poorly differentiated NENs		
Neuroendocrine carcinoma (NEC) G3	>20 %	>20/10 HPF
Small cell type		
Large cell type		

Mixed neuroendocrine-nonneuroendocrine neoplasm (MiNEN)

* Ki67 index is based on at least 500 cells in areas of higher nuclear labeling (“hot spots”); mitoses in 50 high power fields (HPF, 0.2mm²) in areas of higher density and expressed per 10 HPF (2.0 mm²); the final grade based on which ever index (mitotic rate or Ki67) places the tumor in the highest grade category. For assessing Ki67, casual visual estimation (“eyeballing”) is not recommended; manual counting of printed images is suggested

- Changes include Ki67 cut-off > 20%
- Tumors are divided into:
 - Well-differentiated NETs G3 and
 - Poorly differentiated NECs,
- **MANEC** is divided into:
 - MENEN: Mixed endocrine + adenocarcinoma, each component > 30%.
 - MiNEN: Mixed endocrine + non-endocrine other than adenocarcinoma (squamous carcinoma, acinar carcinoma). MiNEN is rarely well differentiated.

NCCN 2018 Classification of Neuroendocrine and Adrenal Tumors


NCCN Guidelines Version 4.2018
Neuroendocrine and Adrenal Tumors
[NCCN Guidelines Index](#)
[Table of Contents](#)
[Discussion](#)

PRINCIPLES OF PATHOLOGY FOR DIAGNOSIS AND REPORTING OF NEUROENDOCRINE TUMORS

Required information:

- Anatomic site of tumor
- Diagnosis
- Grade (See Table 1)
- Mitotic rate and/or Ki-67
- Size of tumor
- Presence of multicentric disease
- Presence of vascular invasion
- Presence of perineural invasion
- Presence of other pathologic components (eg, non-neuroendocrine components)
- Lymph node metastases to include the number of positive nodes and total number of nodes examined
- Margin status (report as positive or negative)
- Assign TNM stage per the AJCC TNM system ([See Staging](#))

Optional information:

- Immunohistochemical staining for general neuroendocrine markers
- Presence of nonischemic tumor necrosis
- Presence of unusual histologic features (eg, oncocytic, clear cell, gland forming)
- Exact distance of tumor to margin(s) if less than 0.5 cm
- Background pathology of organ (ie, PanIN, ECL cell hyperplasia)

Table 1^a

Differentiation	Grade	Gastrointestinal NET (excluding pancreas)	Pancreatic NET ^b	Lung and Thymus
Well-differentiated	Low Grade (G1)	<2 mitoses/10 HPF AND/OR <3% Ki-67 index	<2 mitoses/10 HPF AND <3% Ki-67 index	<2 mitoses/10 HPF AND no necrosis
	Intermediate Grade (G2)	2–20 mitoses/10 HPF AND/OR 3–20% Ki-67 index	2–20 mitoses/10 HPF OR 3%–20% Ki-67 index	2–10 mitoses/10 HPF AND/OR foci of necrosis
	High Grade (G3)		>20 mitoses/10 HPF OR >20% Ki-67 index	
Poorly differentiated	High Grade (G3)	>20 mitoses/10 HPF AND/OR >20% Ki-67 index	>20 mitoses/10 HPF OR >20% Ki-67 index	>10 mitoses/10 HPF

Classification of Neuroendocrine GEP Tumors (GEP-NETs) by Site of Origin

Intestinal neuroendocrine tumors

(carcinoids, about 50% of GEP-NETs)

With carcinoid syndrome

(30% of carcinoids)

Flushing, diarrhea, endocardial fibrosis, wheezing caused by the release of serotonin predominantly from liver metastases.

Without carcinoid syndrome

(70% of carcinoids)

Pancreatic endocrine tumors (PETs)

(~30% of GEP-NETs)

Nonfunctioning (45%–60% of PETs)

Functioning (40%–55% of PETs)

Classification of Neuroendocrine GEP Tumors (GEP-NETs) by Hormonal Activity

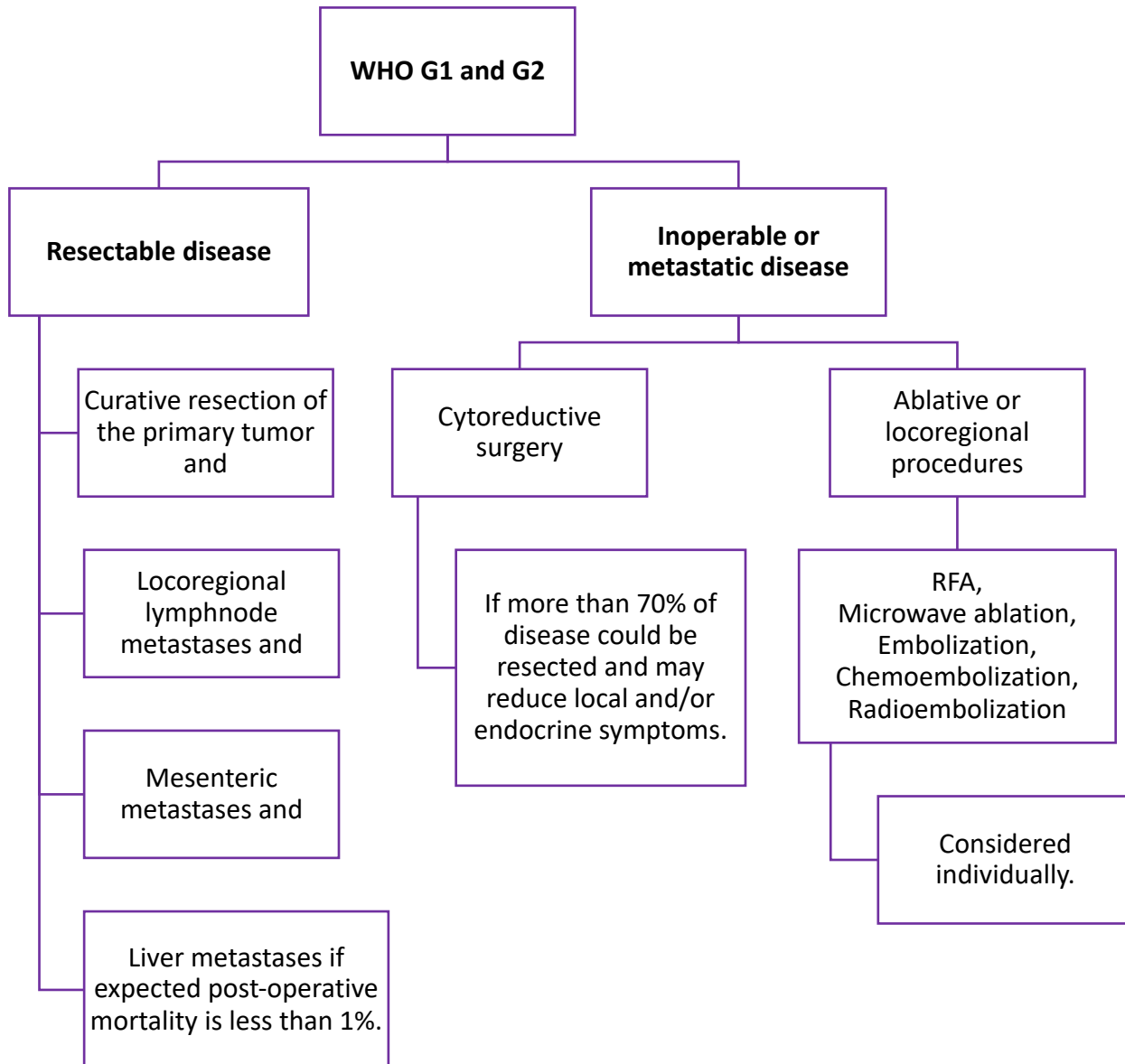
Neuroendocrine GEP tumors (GEP-NETs)

Gastrinoma	Excessive gastrin production, Zollinger–Ellison syndrome
Insulinoma	Excessive insulin production, hypoglycemia syndrome
Glucagonoma	Excessive glucagons production, glucagonoma syndrome
VIPoma	Excessive production of the vasoactive intestinal peptide (VIP) Watery diarrhea, hypokalemia–achlorhydria syndrome
PPoma	Excessive PP production (generally classified as nonfunctioning NETs)
Somatostatinoma	Excessive somatostatin production
CRHoma	Excessive corticotropin-releasing hormones (CRH) production
Calcitoninoma	Excessive calcitonin production
GHRHoma	Excessive growth hormone-releasing hormone (GHRH) production
Neurotensinoma	Excessive neurotensin production
ACTHoma	Excessive production of adrenocorticotrophic hormone (ACTH)
GRFoma	Excessive production of growth hormone-releasing factor (GRF)
Parathyroid hormone-related peptide tumor	

Treatment

MDT presentation is mandatory to plan optimal treatment

(Surgeon, Hepatobiliary surgeon, Endocrinologist, Radiologist, Interventional radiologist, Radiation oncologist, Medical oncologist, Nuclear medicine).



Therapy of endocrine (carcinoid) syndrome:

Octreotide LAR:

- Initial dose: 30 mg IM every 4 weeks
- The dose could be increased if the syndrome is not completely controlled
- Interval could be shortened if symptoms recur before 4 weeks

Regular Octreotide

- Dose: 150 – 205 ng SC TID as initial therapy
- Regular Octreotide is given:
 - To bridge delayed onset of effect of the LAR form (may take up to 14days)
 - Or for breakthrough symptoms.

Octreotide Failure:

- Debulking or
- Ablative therapy or
- PRRT (if imaging receptor positive).
- Telotristat

Telotristat

- Telotristat 250 mg PO TDS.
- Telotristat is not registered in Kuwait, however, may be procured on special request.

Medical systemic therapy for advanced/metastatic disease: WHO G1 and G2

Somatostatin analog (1st Line):

- Somatostatin analog is indicated in both functioning and non-functioning NETs (all GEP-NETs).
- Wait-and-watch could be considered in selected patients (asymptomatic low burden tumor, WHO G1)

At Progression:

- Somatostatin to be continued in functioning tumors.

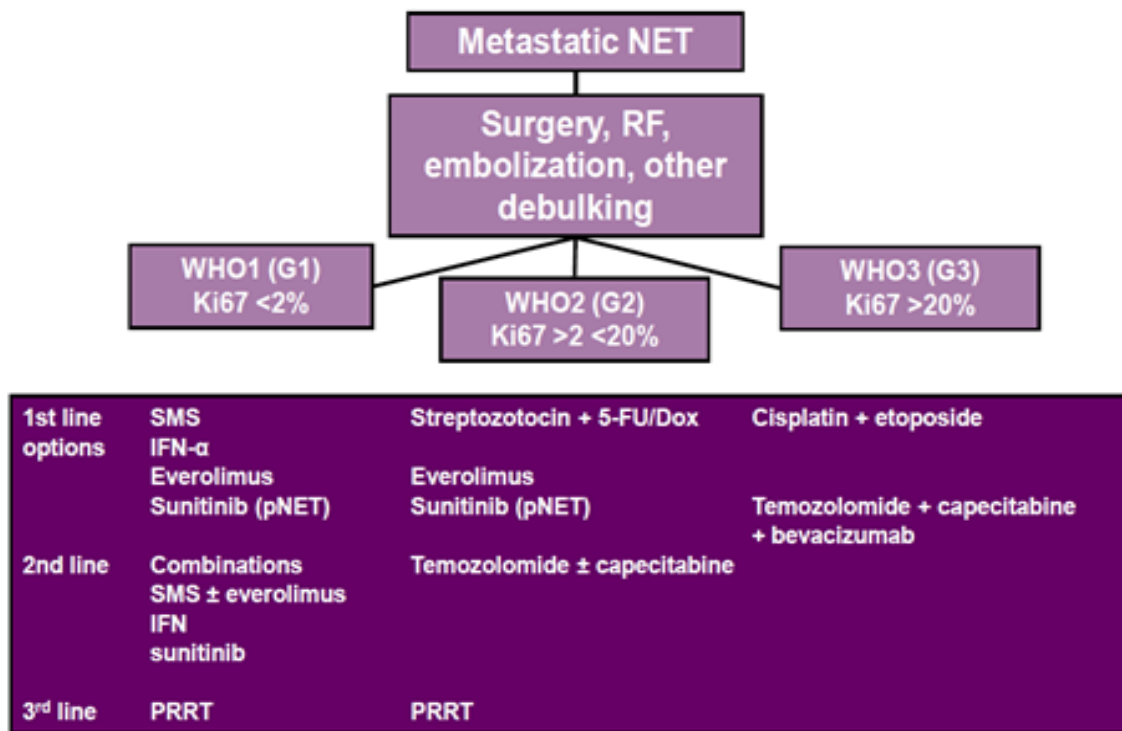
Other options

- [There are no data to suggest optimal sequencing of the following options]:
- Somatostatin analog + Everolimus (all GEP-NETs)
- Everolimus single agent in pancreatic NETs
- Sunitinib single agent in pancreatic NETs
- PRRT (if imaging receptor positive)
- TACE/TARE
- Interferon alpha2b, regular or pegylated (all GEP-NETs) with/without Bevacizumab

Chemotherapy regimens [in WHO 2 GEP-NETs patients with no other feasible options]

- Temozolomide
- Temozolomide + Capecitabine ± Bevacizumab
- 5-FU
- Capecitabine
- FOLFOX
- FOLFIRI
- Dacarbazine
- Streptozocin
- Streptozocin + 5-FU
- Streptozocin + Doxorubicin.

Example of Treatment Algorithm



Medical Therapy for Advanced/Metastatic Disease: WHO 3

- Cisplatin/Carboplatin + Etoposide.
- No established second-line therapy present
- However, Temozolomide with/without capecitabine with/without bevacizumab or FOLFIRI may be considered.

Follow-up:

- Resected GEP-NET G1/2:
 - CT every 6 months,
 - Somatostatin receptor imaging if initially positive every 18-24 months.