

## GASTROESOPHAGEAL CANCER

### Initial Workup

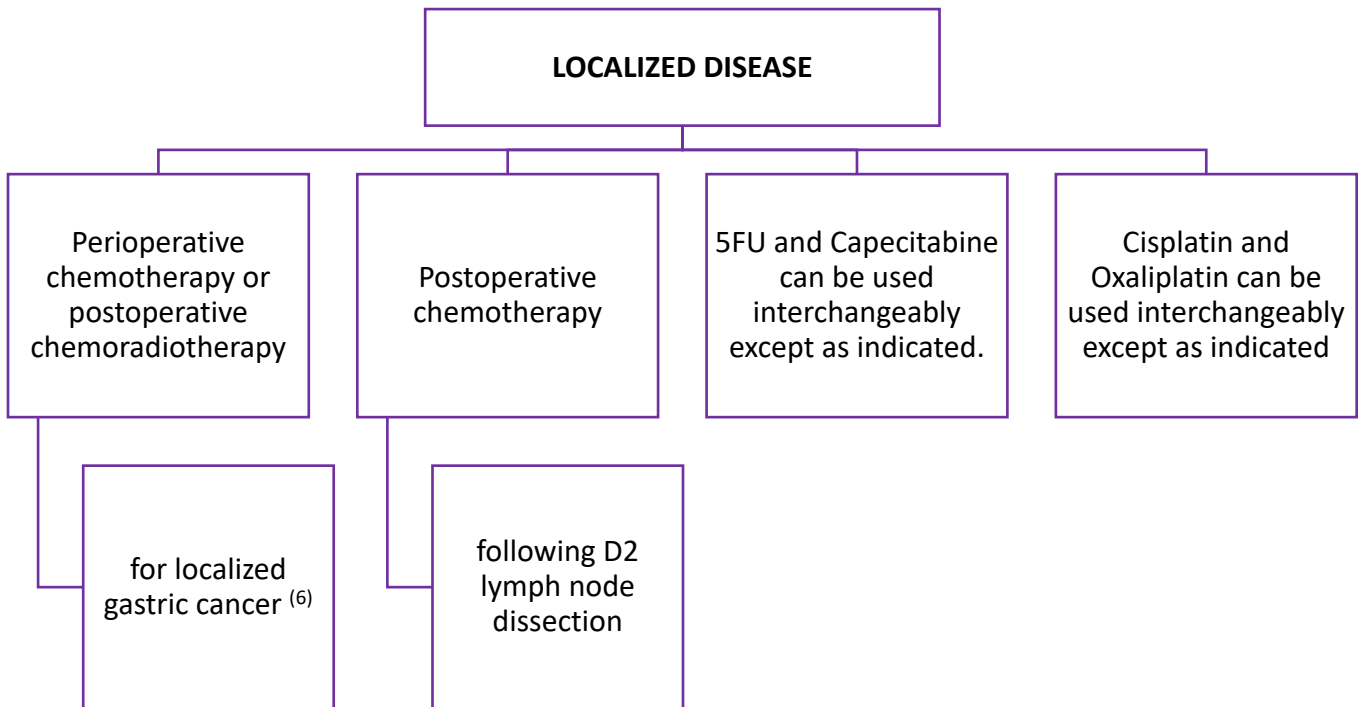
- A thorough history and physical examination
- Routine laboratory tests to assess:
  - Iron deficiency anemia.
  - Liver and kidney functions.
- Upper GI endoscopy and adequate biopsy: to provide tissue diagnosis and molecular biomarkers.
- Laparoscopy in M0 cases planned for definitive treatment (surgery or concurrent chemoradiotherapy) to evaluate for peritoneal spread.  
N.B. Laparoscopy is not indicated if palliative treatment is planned.
- Radiological Assessment:
  - Computerized Tomography (CT) thorax + abdomen ± pelvis for clinical staging.
  - Endoscopic Ultrasound (EUS) for accurate assessment of T and N stage in potentially operable tumors. It determines the proximal and distal extent of tumors.
  - A positron emission tomography (PET) scan [for occult metastasis]:  
PET scan is optional if available. Considered if the result would change the treatment plan. It could be false negative in mucinous and diffuse adenocarcinomas.

*Tumors arising at the esophagogastric junction (EGJ) or in the cardia of the stomach within 5 cm of the EGJ that extend into the EGJ or esophagus are staged and treated as esophageal rather than stomach cancers.*

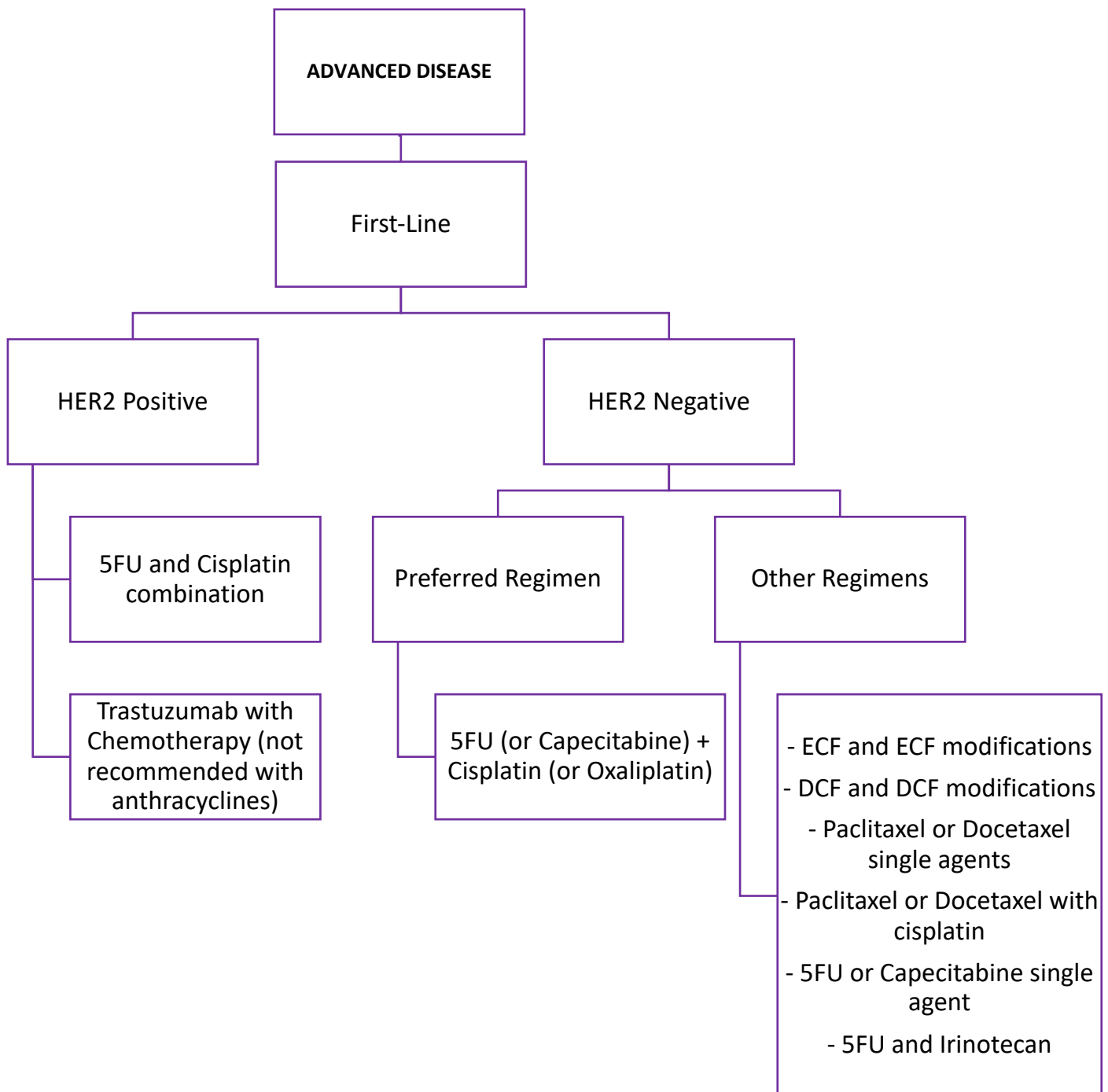
*Tumors that arise beyond 5 cm of the EGJ or are within 5 cm of the EGJ but without extension to the esophagus or EGJ are classified and treated as gastric cancers.*

***The 8th edition of the TNM staging manual***

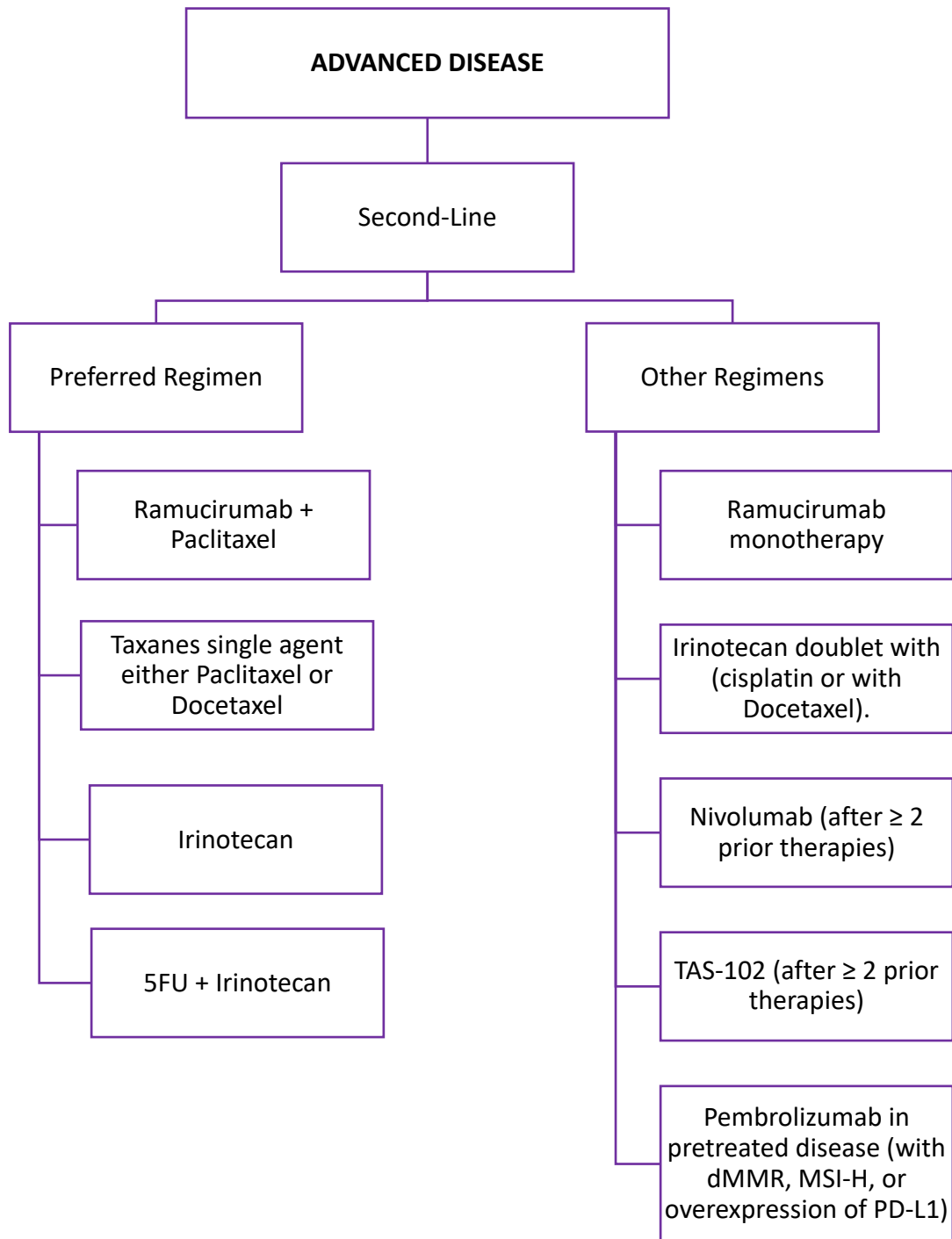
**SUMMARY OF PREFERRED SYSTEMIC CHEMOTHERAPY REGIMENS FOR LOCALIZED DISEASE**



**SUMMARY OF PREFERRED SYSTEMIC CHEMOTHERAPY REGIMENS FOR ADVANCED DISEASE (FIRST-LINE)**



**SUMMARY OF PREFERRED SYSTEMIC CHEMOTHERAPY REGIMENS FOR ADVANCED DISEASE (SECOND-LINE)**



## Principles of Systemic Treatment for Resectable or Localized EGJ/Gastric Cancer

### Perioperative Chemotherapy<sup>(1-4)</sup>: Inclusive of GE Junction Adenocarcinoma

Preferred regimens:

- Two-drug regimen: 5-Fluorouracil (5FU) + Oxaliplatin
- Three-drug regimen: FLOT (5-FU/Leucovorin, Oxaliplatin and Docetaxel) (category 1)

Due to toxicity, the three-drug regimen is recommended only for medically fit patients.

Other regimens:

- 5FU + Cisplatin

### Postoperative Chemoradiation<sup>(5)</sup>: Inclusive of GE Junction Adenocarcinoma

Fluoropyrimidine (infusional fluorouracil or capecitabine) before and after Fluoropyrimidine-based chemoradiation.

### Preoperative Chemoradiation<sup>(7)</sup>: For GE Junction and Gastric Cardia Tumours

Preferred regimens: (category 1)

- Paclitaxel + Carboplatin
- 5FU (or Capecitabine) + Oxaliplatin (or Cisplatin)

Other regimens: (category 2B)

- Paclitaxel + 5FU (or Capecitabine)

### Postoperative Chemotherapy<sup>(6)</sup>: For Patients who have undergone primary D2 Lymph Node Dissection

Capecitabine + Oxaliplatin (category 1).

**I. Perioperative chemotherapy for medically fit cT2 or higher any N (Category 1)**

Regimen	Dose	Supporting Evidence
Perioperative (ECF) or ECF modified based therapy: <ul style="list-style-type: none"> <li>Epirubicin,</li> <li>Cisplatin and</li> <li>Infused 5-fluorouracil</li> </ul>	This approach includes: <ul style="list-style-type: none"> <li>3 preoperative cycles and</li> <li>3 postoperative cycles</li> </ul>	The adoption of this perioperative chemotherapy approach for the treatment of gastric cancer was a result of the MAGIC and the French FNLCC/FFCD trials <sup>(1-3)</sup> .
Perioperative FLOT based therapy [Standard of Care]: <ul style="list-style-type: none"> <li>5-fluorouracil,</li> <li>Leucovorin,</li> <li>Docetaxel, and</li> <li>Oxaliplatin</li> </ul>	This approach includes: <ul style="list-style-type: none"> <li>4 preoperative cycles and</li> <li>4 postoperative cycles</li> </ul>	The results from the more recent Phase III FLOT4-AIO trial showed significant superiority of perioperative 5-fluorouracil, leucovorin, docetaxel, and oxaliplatin (FLOT) compared with ECF <sup>(4)</sup> .

**II. Post-operative management for patients who have not received pre-operative chemotherapy or chemoradiotherapy.****a. Postoperative Chemoradiotherapy (category 1)**

Regimen	Indication	Supporting Evidence
<b>This approach includes:</b> Fluoropyrimidine: <ul style="list-style-type: none"> <li>Infusional 5-FU or</li> <li>Capecitabine</li> </ul> before and after concomitant fluoropyrimidine-based chemoradiation <sup>(5)</sup> .	It is considered the standard approach for completely resected gastric cancer.	It is adapted from the INT0116 study.

**b. Postoperative Chemotherapy (category 1)**

Regimen	Indication	Supporting Evidence
<b>Adjuvant therapy:</b> Postoperative chemotherapy (XELOX).	It is recommended following D2 lymph node dissection.	It is supported by the multicenter CLASSIC trial.

## Principles of Systemic Therapy for Locally Advanced Unresectable Non-Metastatic Disease

- The role of induction therapy in those patients is unclear.
- These cases should be discussed in a multidisciplinary team setting.
- The reasonable approach is an initial attempt at down-staging with:
  - Chemotherapy using regimens for metastatic disease,
  - Chemoradiotherapy, or
  - A combination followed by careful restaging and surgical exploration in responders who have no evidence of metastatic disease.

## Principles of Systemic Therapy for Metastatic Disease

### I. Role of Systemic Chemotherapy

#### **Preferred Regimens:**

- Two-drug cytotoxic regimen
    - *[preferred for patients with advanced disease because of lower toxicity]*
  - Three-drug cytotoxic regimen
    - *[reserved for medically fit patients with good performance status and access to frequent toxicity evaluation]*
- Choice of therapy is based on:
    - Performance status (PS)
    - Practice preference
    - Comorbidities
    - Toxicity profile
    - Possible contraindications
    - Availability of the agents

### II. Role of Targeted Therapy (Anti-HER2)

#### **Preferred Regimens:**

- Trastuzumab (Herceptin) + Chemotherapy (except anthracyclines)

The addition of the human epidermal growth factor receptor 2 (HER2)- targeted therapy trastuzumab (Herceptin) to chemotherapy in the first-line setting has shown a survival benefit for patients with HER2-positive advanced gastric or GEJ cancer, with a median overall survival (OS) of 13.8 months versus 11.1 months with chemotherapy alone. Trastuzumab is not recommended for use with anthracyclines<sup>(8)</sup>.

### III. Role of Targeted Therapy (Angiogenesis Inhibition)

#### **Preferred regimens:**

- Ramucirumab + Paclitaxel

Ramucirumab showed benefit in the second line in both the RAINBOW and REGARD trials. In RAINBOW, ramucirumab was assessed in combination with paclitaxel. The OS was 9.6 months for ramucirumab plus paclitaxel versus 7.4 months for placebo plus paclitaxel. REGARD study showed a survival benefit with ramucirumab monotherapy, but it was more modest than with the ramucirumab and paclitaxel combination in the RAINBOW study<sup>(9, 10)</sup>.

#### IV. Other Chemotherapy Compounds

##### **Preferred Regimens:**

- Trifluridine/Tipiracil (TAS-102; FTD/TPI; Lonsurf)

In the phase III TAGS trial, trifluridine/tipiracil (TAS-102; FTD/TPI; Lonsurf) reduced the risk of death by about one-third compared with placebo in patients with heavily pretreated gastric or GEJ cancer<sup>(11)</sup>.

#### V. Role of Immunotherapy

Data is emerging regarding the role and timing of immunotherapy in the treatment landscape of advanced gastroesophageal cancers<sup>(12-14)</sup>.

##### a) Pembrolizumab:

##### **Suggested Regimens:**

- **Pembrolizumab** in advanced disease (with dMMR, Microsatellite instability-high (MSI-H), or overexpression of the programmed cell death ligand 1 (PD-L1)) and progressing on standard therapy [previously treated with two or more lines of chemotherapy] with no satisfactory alternative option available.

Based on the results of the phase II KEYNOTE-059 study, the FDA approved the anti-PD-1 immunotherapy pembrolizumab (Keytruda) for PD-L1–positive recurrent or advanced gastric or GEJ adenocarcinomas previously treated with two or more lines of chemotherapy.

In phase III KEYNOTE-061 study, Shitara et al., compared pembrolizumab with paclitaxel in patients with advanced gastric or GEJ cancer that progressed on first-line therapy with platinum and fluoropyrimidine and found that it was not as favorable.<sup>(16)</sup> The median OS was 9.1 months with pembrolizumab versus 8.3 months with paclitaxel.

KEYNOTE-061 also included PD-L1–negative patients with advanced gastric or GEJ cancer, and a post hoc analysis showed benefit with increased PD-L1 expression. A higher PD-L1 expression showed a higher benefit [with pembrolizumab], with a hazard ratio of 0.64 compared with paclitaxel [in patients with a PD-L1 combined positive score (CPS) of  $\geq 10$ ]. The treatment with pembrolizumab also improved OS in patients with a CPS  $\geq 5$ , with an HR of 0.73.

The hypothesis that MSI-H/dMMR tumors might be particularly susceptible to immune checkpoint inhibition with PD-1 inhibitors was addressed in a proof of concept study in which 86 patients including



advanced gastroesophageal cancer, whose tumors were dMMR were treated with pembrolizumab. Objective radiographic responses were observed in 53 % of patients, and 21% had complete responses. Pembrolizumab may represent a treatment option for patients who have advanced disease (with dMMR, MSI-H, or overexpression of the programmed cell death ligand 1 (PD-L1)) and progressing on standard therapy with no satisfactory alternative option available <sup>(12, 15, 16)</sup>.

#### b) Nivolumab:

##### **Suggested regimens:**

- **Nivolumab** in the advanced disease who had failed two or more standard chemotherapy regimens.

The ATTRACTION-2 trial is a phase 3 trial that evaluated the role of nivolumab in Asian patients with advanced gastric or EGJ cancer who had failed two or more standard chemotherapy regimens. The objective response rate with nivolumab was 11 percent, and median overall survival was improved compared with placebo (5.3 versus 4.1 months [HR 0.63, 95% CI 0.51-0.78], 12-month survival 27 versus 11 percent); median PFS was also improved (1.61 versus 1.45 months [HR 0.60 95% CI 0.49-0.75]).

A comparable degree of benefit in Western populations was suggested in the phase II trial CheckMate 032. Therapy with nivolumab was not restricted to patients expressing a PD-L1 or dMMR/MSI-H tumors <sup>(17, 18)</sup>.

### PREFERRED SYSTEMIC CHEMOTHERAPY REGIMENS FOR ADVANCED DISEASE

#### FIRST-LINE THERAPY

##### **HER2 Positive Disease:**

- Trastuzumab should be added to first-line chemotherapy for HER2 overexpressing advanced disease
- Trastuzumab combination with 5FU and cisplatin (category 1).
- Trastuzumab is not recommended for use with anthracyclines.

##### **HER2 Negative Disease:**

- 5FU (or Capecitabine) + Cisplatin (or Oxaliplatin) (category 1).

##### **Other Regimens:** <sup>(22-38)</sup>

- ECF and ECF modifications
- DCF and DCF modifications
- Paclitaxel or Docetaxel single agents
- Paclitaxel or Docetaxel with cisplatin
- 5FU or Capecitabine single agent
- 5FU and irinotecan

**SECOND-LINE OR SUBSEQUENT THERAPY:**

Dependent on prior therapy and performance status patient maybe <sup>(9-12, 15-18, 39-44)</sup>

**Preferred Regimens:**

- Ramucirumab + Paclitaxel (category 1).
- Taxanes single agent, either Paclitaxel or Docetaxel (category 1).
- Irinotecan (category 1).
- 5FU + Irinotecan (category 1).

**Other Regimens:**

- Ramucirumab monotherapy (category 1).
- Irinotecan doublet with (cisplatin or wit Docetaxel).
- Nivolumab (after  $\geq 2$  prior therapies).
- TAS-102 (after  $\geq 2$  prior therapies and depending on availability).
- Pembrolizumab may represent an option for the pretreated disease [with dMMR, MSI-H, or overexpression of the programmed cell death ligand 1 (PD-L1).

**Further Considerations in the Palliative Approach for Advanced Disease**

- **Obstruction:** Stent, laser, radiotherapy (RT), or surgery
- **Pain:** Medication  $\pm$  RT
- **Bleeding:** RT, surgery, endoscopic therapy
- Nutritional support

**Post-Treatment Cancer Surveillance**

There are no randomized trials to guide the postoperative surveillance strategy. Consensus-based guidelines from the National Comprehensive Cancer Network (NCCN) suggests the following:

- **History and physical examination:** Every three to six months for 1 – 3 years, then  
Every six months for years 4 and 5, then  
As clinically indicated afterward
- CBC and chemistry profile: As clinically indicated
- Radiologic imaging or endoscopy: As clinically indicated
- Nutritional deficiency in surgically treated patients: Monitor and treat as indicated

**Hereditary diffuse gastric cancer:**

Prophylactic total gastrectomy is recommended between ages 18 and 40 for CDH1 mutation carriers.

**Lynch syndrome (LS):**

Selected individuals or families or those of Asian descent may consider esophagogastroduodenoscopy (EGD) with extended duodenoscopy.

## References

- 1) Ychou M, Boige V, Pignon JP, Conroy T, Bouche O, Lebreton G, et al. Perioperative chemotherapy compared with surgery alone for resectable gastroesophageal adenocarcinoma: an FNCLCC and FFCD multicenter phase III trial. *J Clin Oncol*. 2011;29(13):1715-21.
- 2) Cunningham D, Allum WH, Stenning SP, Thompson JN, Van de Velde CJ, Nicolson M, et al. Perioperative chemotherapy versus surgery alone for resectable gastroesophageal cancer. *N Engl J Med*. 2006;355(1):11-20.
- 3) Sumpter K, Harper-Wynne C, Cunningham D, Rao S, Tebbutt N, Norman AR, et al. Report of two protocol planned interim analyses in a randomised multicentre phase III study comparing capecitabine with fluorouracil and oxaliplatin with cisplatin in patients with advanced oesophagogastric cancer receiving ECF. *Br J Cancer*. 2005;92(11):1976-83.
- 4) Al-Batran SE, Hartmann JT, Hofheinz R, Homann N, Rethwisch V, Probst S, et al. Biweekly fluorouracil, leucovorin, oxaliplatin, and docetaxel (FLOT) for patients with metastatic adenocarcinoma of the stomach or esophagogastric junction: a phase II trial of the Arbeitsgemeinschaft Internistische Onkologie. *Annals of oncology : official journal of the European Society for Medical Oncology*. 2008;19(11):1882-7.
- 5) Smalley SR, Benedetti JK, Haller DG, Hundahl SA, Estes NC, Ajani JA, et al. Updated analysis of SWOG-directed intergroup study 0116: a phase III trial of adjuvant radiochemotherapy versus observation after curative gastric cancer resection. *J Clin Oncol*. 2012;30(19):2327-33.
- 6) Noh SH, Park SR, Yang HK, Chung HC, Chung IJ, Kim SW, et al. Adjuvant capecitabine plus oxaliplatin for gastric cancer after D2 gastrectomy (CLASSIC): 5-year follow-up of an open-label, randomised phase 3 trial. *Lancet Oncol*. 2014;15(12):1389-96.
- 7) van Hagen P, Hulshof MC, van Lanschot JJ, Steyerberg EW, van Berge Henegouwen MI, Wijnhoven BP, et al. Preoperative chemoradiotherapy for esophageal or junctional cancer. *N Engl J Med*. 2012;366(22):2074-84.
- 8) Bang YJ, Van Cutsem E, Feyereislova A, Chung HC, Shen L, Sawaki A, et al. Trastuzumab in combination with chemotherapy versus chemotherapy alone for treatment of HER2-positive advanced gastric or gastro-oesophageal junction cancer (ToGA): a phase 3, open-label, randomised controlled trial. *Lancet*. 2010;376(9742):687-97.
- 9) Wilke H, Muro K, Van Cutsem E, Oh SC, Bodoky G, Shimada Y, et al. Ramucirumab plus paclitaxel versus placebo plus paclitaxel in patients with previously treated advanced gastric or gastro-oesophageal junction adenocarcinoma (RAINBOW): a double-blind, randomised phase 3 trial. *Lancet Oncol*. 2014;15(11):1224-35.
- 10) Fuchs CS, Tomasek J, Yong CJ, Dumitru F, Passalacqua R, Goswami C, et al. Ramucirumab monotherapy for previously treated advanced gastric or gastro-oesophageal junction adenocarcinoma (REGARD): an international, randomised, multicentre, placebo-controlled, phase 3 trial. *Lancet*. 2014;383(9911):31-9.
- 11) Arkenau H-T, Tabernero J, Shitara K, et al. TAGS: a phase 3, randomised, double-blind study of trifluridine/tipiracil (TAS-102) versus placebo in patients with refractory metastatic gastric cancer. *Ann Oncol*. 2018;29(suppl 8; abstr LBA25).

- 12) Le DT, Durham JN, Smith KN, Wang H, Bartlett BR, Aulakh LK, et al. Mismatch repair deficiency predicts response of solid tumors to PD-1 blockade. *Science (New York, NY)*. 2017;357(6349):409-13.
- 13) Le DT, Uram JN, Wang H, Bartlett BR, Kemberling H, Eyring AD, et al. PD-1 Blockade in Tumors with Mismatch-Repair Deficiency. *N Engl J Med*. 2015;372(26):2509-20.
- 14) Burtneß B, Gibson M, Egleston B, Mehra R, Thomas L, Sipples R, et al. Phase II trial of docetaxel-irinotecan combination in advanced esophageal cancer. *Annals of oncology: official journal of the European Society for Medical Oncology*. 2009;20(7):1242-8.
- 15) Fuchs CS, Doi T, Jang RW, Muro K, Satoh T, Machado M, et al. Safety and Efficacy of Pembrolizumab Monotherapy in Patients With Previously Treated Advanced Gastric and Gastroesophageal Junction Cancer: Phase 2 Clinical KEYNOTE-059 Trial. *JAMA oncology*. 2018;4(5):e180013.
- 16) Shitara K, Ozguroglu M, Bang YJ, Di Bartolomeo M, Mandala M, Ryu MH, et al. Pembrolizumab versus paclitaxel for previously treated, advanced gastric or gastro-oesophageal junction cancer (KEYNOTE-061): a randomised, open-label, controlled, phase 3 trial. *Lancet*. 2018;392(10142):123-33.
- 17) Kang YK, Boku N, Satoh T, Ryu MH, Chao Y, Kato K, et al. Nivolumab in patients with advanced gastric or gastro-oesophageal junction cancer refractory to, or intolerant of, at least two previous chemotherapy regimens (ONO-4538-12, ATTRACTION-2): a randomised, double-blind, placebo-controlled, phase 3 trial. *Lancet*. 2017;390(10111):2461-71.
- 18) Janjigian YY, Bendell J, Calvo E, Kim JW, Ascierto PA, Sharma P, et al. CheckMate-032 Study: Efficacy and Safety of Nivolumab and Nivolumab Plus Ipilimumab in Patients With Metastatic Esophagogastric Cancer. *J Clin Oncol*. 2018;36(28):2836-44.
- 19) Al-Batran SE, Hartmann JT, Probst S, Schmalenberg H, Hollerbach S, Hofheinz R, et al. Phase III trial in metastatic gastroesophageal adenocarcinoma with fluorouracil, leucovorin plus either oxaliplatin or cisplatin: a study of the Arbeitsgemeinschaft Internistische Onkologie. *J Clin Oncol*. 2008;26(9):1435-42.
- 20) Bouche O, Raoul JL, Bonnetain F, Giovannini M, Etienne PL, Lledo G, et al. Randomized multicenter phase II trial of a biweekly regimen of fluorouracil and leucovorin (LV5FU2), LV5FU2 plus cisplatin, or LV5FU2 plus irinotecan in patients with previously untreated metastatic gastric cancer: a Federation Francophone de Cancerologie Digestive Group Study--FFCD 9803. *J Clin Oncol*. 2004;22(21):4319-28.
- 21) Kang YK, Kang WK, Shin DB, Chen J, Xiong J, Wang J, et al. Capecitabine/cisplatin versus 5-fluorouracil/cisplatin as first-line therapy in patients with advanced gastric cancer: a randomised phase III noninferiority trial. *Annals of oncology : official journal of the European Society for Medical Oncology*. 2009;20(4):666-73.
- 22) Kim GM, Jeung HC, Rha SY, Kim HS, Jung I, Nam BH, et al. A randomized phase II trial of S-1-oxaliplatin versus capecitabine-oxaliplatin in advanced gastric cancer. *European journal of cancer (Oxford, England : 1990)*. 2012;48(4):518-26.
- 23) Ilson DH, Forastiere A, Arquette M, Costa F, Heelan R, Huang Y, et al. A phase II trial of paclitaxel and cisplatin in patients with advanced carcinoma of the esophagus. *Cancer journal (Sudbury, Mass)*. 2000;6(5):316-23.

- 24) Petrasch S, Welt A, Reinacher A, Graeven U, Konig M, Schmiegel W. Chemotherapy with cisplatin and paclitaxel in patients with locally advanced, recurrent or metastatic oesophageal cancer. *Br J Cancer*. 1998;78(4):511-4.
- 25) Gadgeel SM, Shields AF, Heilbrun LK, Labadidi S, Zalupski M, Chaplen R, et al. Phase II study of paclitaxel and carboplatin in patients with advanced gastric cancer. *American journal of clinical oncology*. 2003;26(1):37-41.
- 26) Ajani JA, Fodor MB, Tjulandin SA, Moiseyenko VM, Chao Y, Cabral Filho S, et al. Phase II multi-institutional randomized trial of docetaxel plus cisplatin with or without fluorouracil in patients with untreated, advanced gastric, or gastroesophageal adenocarcinoma. *J Clin Oncol*. 2005;23(24):5660-7.
- 27) Kim JY, Do YR, Park KU, Kim MK, Lee KH, Bae SH, et al. A multi-center phase II study of docetaxel plus cisplatin as first-line therapy in patients with metastatic squamous cell esophageal cancer. *Cancer chemotherapy and pharmacology*. 2010;66(1):31-6.
- 28) Ohtsu A, Shimada Y, Shirao K, Boku N, Hyodo I, Saito H, et al. Randomized phase III trial of fluorouracil alone versus fluorouracil plus cisplatin versus uracil and tegafur plus mitomycin in patients with unresectable, advanced gastric cancer: The Japan Clinical Oncology Group Study (JCOG9205). *J Clin Oncol*. 2003;21(1):54-9.
- 29) Hong YS, Song SY, Lee SI, Chung HC, Choi SH, Noh SH, et al. A phase II trial of capecitabine in previously untreated patients with advanced and/or metastatic gastric cancer. *Annals of oncology : official journal of the European Society for Medical Oncology*. 2004;15(9):1344-7.
- 30) Albertsson M, Johansson B, Friesland S, Kadar L, Letocha H, Frykholm G, et al. Phase II studies on docetaxel alone every third week, or weekly in combination with gemcitabine in patients with primary locally advanced, metastatic, or recurrent esophageal cancer. *Medical oncology (Northwood, London, England)*. 2007;24(4):407-12.
- 31) Ford HE, Marshall A, Bridgewater JA, Janowitz T, Coxon FY, Wadsley J, et al. Docetaxel versus active symptom control for refractory oesophagogastric adenocarcinoma (COUGAR-02): an open-label, phase 3 randomised controlled trial. *Lancet Oncol*. 2014;15(1):78-86.
- 32) Ajani JA, Ilson DH, Daugherty K, Pazdur R, Lynch PM, Kelsen DP. Activity of taxol in patients with squamous cell carcinoma and adenocarcinoma of the esophagus. *J Natl Cancer Inst*. 1994;86(14):1086-91.
- 33) Ilson DH, Wadleigh RG, Leichman LP, Kelsen DP. Paclitaxel given by a weekly 1-h infusion in advanced esophageal cancer. *Annals of oncology: official journal of the European Society for Medical Oncology*. 2007;18(5):898-902.
- 34) Guimbaud R, Louvet C, Ries P, Ychou M, Maillard E, Andre T, et al. Prospective, randomized, multicenter, phase III study of fluorouracil, leucovorin, and irinotecan versus epirubicin, cisplatin, and capecitabine in advanced gastric adenocarcinoma: a French intergroup (Federation Francophone de Cancerologie Digestive, Federation Nationale des Centres de Lutte Contre le Cancer, and Groupe Cooperateur Multidisciplinaire en Oncologie) study. *J Clin Oncol*. 2014;32(31):3520-6.
- 35) Shah MA, Janjigian YY, Stoller R, Shibata S, Kemeny M, Krishnamurthi S, et al. Randomized Multicenter Phase II Study of Modified Docetaxel, Cisplatin, and Fluorouracil (DCF) Versus DCF Plus

- Growth Factor Support in Patients With Metastatic Gastric Adenocarcinoma: A Study of the US Gastric Cancer Consortium. *J Clin Oncol*. 2015;33(33):3874-9.
- 36) Shankaran V, Mulcahy MF, Hochster HS, et al. Docetaxel, oxaliplatin, and 5- fluorouracil for the treatment of metastatic or unresectable gastric or gastroesophageal junction (GEJ) adenocarcinomas: Preliminary results of a phase II study. *Gastrointestinal Cancers Symposium 2009*: Abstract 47.
- 37) Elkerm YM, Elsaid A, AL-Batran S, Pauligk C. Final results of a phase II trial of docetaxel- carboplatin- FU in locally advanced gastric carcinoma Labstract [Abstract]. Presented at the 2008 *Gastrointestinal Cancers Symposium 2008*. Abstract
- 38) Ross P, Nicolson M, Cunningham D, Valle J, Seymour M, Harper P, et al. Prospective randomized trial comparing mitomycin, cisplatin, and protracted venous-infusion fluorouracil (PVI 5-FU) With epirubicin, cisplatin, and PVI 5-FU in advanced esophagogastric cancer. *J Clin Oncol*. 2002;20(8):1996-2004.
- 39) Hironaka S, Ueda S, Yasui H, Nishina T, Tsuda M, Tsumura T, et al. Randomized, open-label, phase III study comparing irinotecan with paclitaxel in patients with advanced gastric cancer without severe peritoneal metastasis after failure of prior combination chemotherapy using fluoropyrimidine plus platinum: WJOG 4007 trial. *J Clin Oncol*. 2013;31(35):4438-44.
- 40) Sym SJ, Hong J, Park J, Cho EK, Lee JH, Park YH, et al. A randomized phase II study of biweekly irinotecan monotherapy or a combination of irinotecan plus 5-fluorouracil/leucovorin (mFOLFIRI) in patients with metastatic gastric adenocarcinoma refractory to or progressive after first-line chemotherapy. *Cancer chemotherapy and pharmacology*. 2013;71(2):481-8.
- 41) Thuss-Patience PC, Kretzschmar A, Bichev D, Deist T, Hinke A, Breithaupt K, et al. Survival advantage for irinotecan versus best supportive care as second-line chemotherapy in gastric cancer--a randomised phase III study of the Arbeitsgemeinschaft Internistische Onkologie (AIO). *European journal of cancer (Oxford, England : 1990)*. 2011;47(15):2306-14.
- 42) Fuchs CS, Moore MR, Harker G, Villa L, Rinaldi D, Hecht JR. Phase III comparison of two irinotecan dosing regimens in second-line therapy of metastatic colorectal cancer. *J Clin Oncol*. 2003;21(5):807-14.
- 43) Sym SJ, Ryu MH, Lee JL, Chang HM, Kim TW, Lee SS, et al. Salvage chemotherapy with biweekly irinotecan, plus 5-fluorouracil and leucovorin in patients with advanced gastric cancer previously treated with fluoropyrimidine, platinum, and taxane. *American journal of clinical oncology*. 2008;31(2):151-6.
- 44) Assersohn L, Brown G, Cunningham D, Ward C, Oates J, Waters JS, et al. Phase II study of irinotecan and 5-fluorouracil/leucovorin in patients with primary refractory or relapsed advanced oesophageal and gastric carcinoma. *Annals of oncology : official journal of the European Society for Medical Oncology*. 2004;15(1):64-9.