

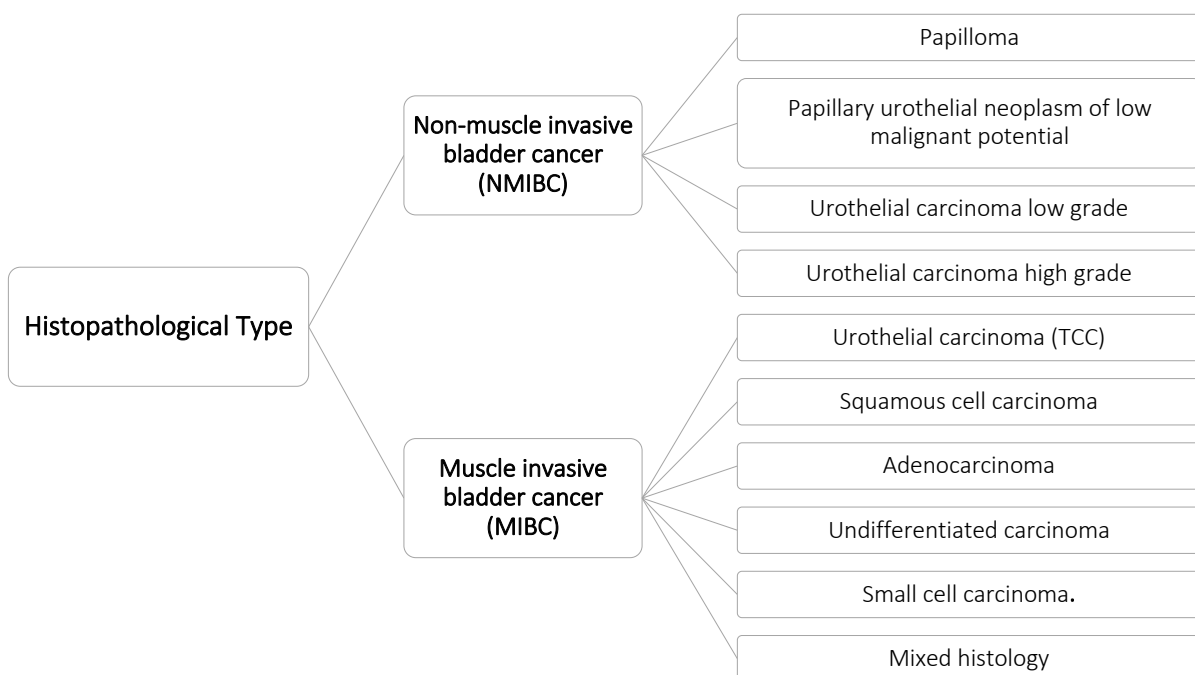
URINARY BLADDER CANCER

Initial Workup

- History:
 - Hematuria and dysuria
- Physical examination.
- Laboratory Investigations:
 - CBC, chemistry profile
 - Creatinine clearance
- Urine cytology
- Examination under anesthesia (bimanual examination).
- Cystoscopy and transurethral resection (TUR) (follow standardized protocol).
- Histopathological examination.
- Staging work up
 - CT urography
 - Chest X-ray
 - CT scan abdomen and pelvis.
 - CT scan chest (optional if clinically indicated).
 - Bone scan (optional if clinically indicated).

Pathology

The report should include histological type, grade, depth of invasion, presence of carcinoma in situ (CIS), and LN status **(According to the WHO and International Society of Urological Pathology (ISUP))**.



Staging

(According to American Joint Committee on Cancer (AJCC) and TNM staging system 7th ed., 2010)

Tumor	
TX	The primary tumor cannot be evaluated
T0	No evidence of a primary tumor in the bladder
Ta	Noninvasive papillary carcinoma
Tis	Carcinoma in situ, or "flat tumor." cancer found in cells within the lining of the bladder
T1	The tumor has spread to the subepithelial connective tissue
T2	The tumor has spread to the muscle of the bladder wall
T2a	The tumor has spread to the inner half of the muscle of the bladder wall
T2b	The tumor has spread to the deep muscle of the bladder
T3	The tumor has grown into the perivesical tissue
T3a	Microscope growth into the perivesical tissue
T3b	Macroscopic growth into the perivesical tissue
T4	The tumor has spread to any of the following: the abdominal wall, the pelvic wall, prostate or seminal vesicle in male patients or to the uterus or vagina in female patients
T4a	The tumor has spread to the prostate, uterus, or vagina
T4b	The tumor has spread to the pelvic wall or the abdominal wall

Lymph Node	
NX	The regional lymph nodes cannot be evaluated
N0	Cancer has not spread to the regional lymph nodes
N1	Cancer has spread to a single regional lymph node in the pelvis
N2	Cancer has spread to more than one regional lymph node in the pelvis
N3	Cancer has spread to the common iliac lymph nodes

Metastasis	
M0	The disease has not metastasized
M1	There is distant metastasis

Cancer Stage Grouping			
Stage 0a	Ta	N0	M0
Stage 0is	Tis	N0	M0
Stage I	T1	N0	M0
Stage II	T2	N0	M0
Stage III	T3 or T4	N0	M0
Stage IV	T4b	N0	M0
	Any T	N1-3	M0
	Any T	Any N	M1

Treatment

Stage I (NMIBC, T1, N0M0)

Complete transurethral resection of bladder tumor (TURBT) is the treatment of choice.

If incomplete resection or no muscle in the specimen consider repeats TURBT, followed by:

Intravesical chemotherapy or

Careful surveillance in patients with low-risk disease.

Patients with high-risk disease (recurrent, large, deeply invasive, multifocal, poorly differentiated or with CIS) can be treated with intravesical Bacillus Calmette-Guerin (BCG) therapy after initial TUR or radical cystectomy if still residual disease.

If there is no response to BCG, cystectomy should be considered.

N.B. Refers to Mitomycin and BCG administration guidelines (under radiotherapy or urologist).

Stage II (MIBC, T2a or T2b N0 M0).

Stage III (MIBC, T3a or T3b or T4a N0 M0).

Surgical treatment

Radical cystectomy with extended lymphadenectomy (common iliac, lower para-aortic and paracaval) is usually considered to be the standard treatment.

Reconstruction may be performed by either ileal conduit or bladder replacement depending on tumor characteristics and the patient's choice.

Partial cystectomy can be considered in less than 5% of patients with special characteristics as a tumor at the bladder dome, no Tis, 2 cm safety margin without compromising continence or bladder capacity.

Neoadjuvant chemotherapy

There is increasing evidence to support the use of neoadjuvant chemotherapy in the treatment of muscle invasive bladder cancer (MIBC).

Many Randomized Clinical Trials (RCT) and meta-analysis showed improvement of 5-year survival and disease-free survival of 5% and 9% respectively with the use of platinum-based chemotherapy mainly DDMVAC or CMV or GC for 3 or 4 cycles.

Carboplatin should not substitute Cisplatin in a perioperative setting in normal patients.

Adjuvant chemotherapy

There is insufficient evidence for the routine use of adjuvant chemotherapy in clinical practice.

However, based on retrospective studies showing some benefit of adjuvant chemotherapy has been reported in patients with:

Advanced stage,

Node-positive patients, and

Lymphovascular infiltration (LVI).

Minimum of 3 cycles of platinum-based chemotherapy as (DDMVAC, CG, and CMV) may be considered, further cycles may be offered for some patients taking into consideration their tolerance and side effects of therapy .

Carboplatin should not be substitute Cisplatin in normal patients.

No data supported the use of adjuvant treatment in the nonepithelial tumor, regardless of the stage.

Bladder Preservation Strategies (Trimodality Treatment)

- **Bladder-preserving approach is a reasonable alternative to cystectomy which showed:**
 - A complete remission rate of 64% to 77%,
 - 10-year disease-specific survival (DSS) of 40% to 60% and
 - Recurrence-free survival of about 65%, with almost 80% of survivors preserving their bladders.
- **Clinical criteria helpful in determining ideal patients for bladder preservation include:**
 - Patients who refused cystectomy and seeking an alternative.
 - Medically unfit for surgery.
 - Early tumor stage (including high-risk T1 disease)
 - T2 <5 cm
 - A visibly complete TURBT
 - Absence of associated CIS
 - Ureteral obstruction
 - Adequate bladder capacity and function.

- **The most common protocol used in this modality is the RTOG protocols which include:**
 - Complete treatment with transurethral resection of bladder tumor (TURBT),
 - Concurrent chemo/radiotherapy (40 Gy/2Gy/f with Cisplatin)
 - Cystoscopy assessment and biopsy.
- **Complete responders received consolidation radiation with an additional 24 Gy along with additional Cisplatin.**

Radiotherapy in Bladder Cancer

- External beam radiotherapy (EBRT) alone may be considered as a therapeutic option when the patient is unfit for cystectomy or for trimodality management.
- Adjuvant radiotherapy can be considered in patients with pT3 – pT4, positive margin, positive LN.

Stage IV disease (advanced and metastatic disease)

- Cisplatin-containing combination chemotherapy with gemcitabine (GC) or DDMVAC is standard in patients who are fit enough to tolerate Cisplatin.
 - DDMVAC with G-CSF is less toxic and obtaining a higher response rate than standard MVAC.
 - Many RCTs showed standard MVAC is inferior to dose-dense MVAC and GC in both toxicity and efficacy.
 - The addition of paclitaxel to GC resulted in a higher response rate but with a borderline survival benefit, that did not reach statistical significance.
 - Recently, Vinflunine has been approved for second-line treatment as a valuable option after failure of a platinum-containing regimen.
 - Bellmount et al, in their phase III trial represented that, the median OS was 6.9 months and 4.6 months for Vinflunine plus best supportive care (BSC) Vs BSC alone, respectively. Their data revealed an estimated 22 % reduction in the risk of death.
 - In patients who are not cisplatin-eligible, atezolizumab or pembrolizumab are now appropriate first-line options.
 - Pembrolizumab, atezolizumab, nivolumab, durvalumab, and avelumab are approved for the treatment of locally advanced or metastatic urothelial cell carcinoma that has progressed during or after platinum-based chemotherapy or that has progressed within 12 months of neoadjuvant or adjuvant platinum-containing chemotherapy, regardless of PD-L1 expression levels.
- Special Considerations:**
- Performance status (Karnofsky PS) of (80%) and the presence of visceral metastases are independent poor prognostic factors for survival.
 - Carboplatin can substitute Cisplatin in patients with GFR < 60ml/min.
 - Palliative radiotherapy may be used to reduce symptoms such as pain or bleeding.

NON-UROTHELIAL CELL CARCINOMA OF THE BLADDER

Mixed histology:

- Follow urothelial carcinoma of the bladder with less response and unfavorable prognosis.

Small-cell carcinoma:

- Neoadjuvant chemotherapy using regimens similar to small cell lung cancer followed by
- Local treatment including cystectomy or radiotherapy.

Adenocarcinoma:

- Surgery is the treatment of choice in localized disease.
- The role of adjuvant or neoadjuvant chemotherapy is not well defined.

Squamous cell carcinoma:

- Radical cystectomy provides the best option.

Adjuvant and neoadjuvant CT has inconclusive results but can be used according to clinical judgment.

Chemotherapy Regimens

Regimen		Dosage
Cisplatin/ Gemcitabine	Gemcitabine	1 g/m ² D1, D8 & D15 every 28 days or 1 g/m ² D1 & D8 every 21 days
	Cisplatin	70 mg/m ² every 21 days
DDMVAC	Methotrexate	30 mg/m ² on D1 or D2 every 14-day cycle
	Vinblastine	3 mg/m ² on D1 or D2
	Doxorubicin	30 mg/m ² on D1 or D2
	Cisplatin	70 mg/m ² on D1
CMV	Methotrexate	30 mg/m ² D1 & D8 every 21-day cycle
	Vinblastine	4 mg/m ² on D1 & D8
	Cisplatin	100 mg/m ² on D2
	Folinic acid	15 mg every 6 hours on days 2 and 9 after hydration
Vinflunine	VFL	320 mg/m ² every 21 days as a 20-minute infusion.

Follow Up

- Patients treated with a bladder-preservation strategy, cystoscopy and urinary cytology should be followed up:
 - Every 3 months during the first 2 years, and
 - Every 6 months thereafter.
- After cystectomy, clinical control should take place:
 - Every 3 months during the first 2 years then
 - Every 6 months for 5 years.

References

- 1) Goossens-Laan CA, Gooiker GA, van Gijn W, et al. A systematic review and meta-analysis of the relationship between hospital/surgeon volume and outcome for radical cystectomy: an update for the ongoing debate. *Eur Urol.* 2011;59(5):775-83.
- 2) Pruthi RS, Nielsen M, Smith A, et al. Fast track program in patients undergoing radical cystectomy: results in 362 consecutive patients. *J Am Coll Surg.* 2010;210(1):93-9.
- 3) Canter D, Long C, Kutikov A, et al. Clinicopathological outcomes after radical cystectomy for clinical T2 urothelial carcinoma: further evidence to support the use of neoadjuvant chemotherapy. *BJU Int.* 2011;107(1):58-62.
- 4) International Collaboration of Trialists; Medical Research Council Advanced Bladder Cancer Working Party (now the National Cancer Research Institute Bladder Cancer Clinical Studies Group); European Organisation for Research and Treatment of Cancer Genito-Urinary Tract Cancer Group; et al. International phase III trial assessing neoadjuvant cisplatin, methotrexate, and vinblastine chemotherapy for muscle-invasive bladder cancer: long-term results of the BA06 30894 trial. *J Clin Oncol.* 2011;29:2171-7.
- 5) Raj GV, Karavadia S, Schlomer B, et al. Contemporary use of perioperative cisplatin-based chemotherapy in patients with muscle-invasive bladder cancer. *Cancer.* 2011;117(2):276-82.
- 6) Solsona E, Climent MA, Iborra I, et al. Bladder preservation in selected patients with muscle-invasive bladder cancer by complete transurethral resection of the bladder plus systemic chemotherapy: long-term follow-up of a phase 2 nonrandomized comparative trial with radical cystectomy. *Eur Urol.* 2009;55:911-9.
- 7) Wang L-J, Wong Y-C, Ng K-F, et al. Tumor characteristics of urothelial carcinoma on multidetector computerized tomography urography. *J Urol.* 2010; 183(6):2154-60.
- 8) James ND, Hussien SA, Hall A, et al. Radiotherapy with and without chemotherapy in muscle invasive bladder cancer. *N Engl J Med.* 2012; 366:1477-1488.
- 9) Efstathiou JA, Spiegel DY, Shipley WU, et al. long term outcome of selective bladder preservation by combined modality therapy for invasive bladder cancer. The MGH experience. *EurUro.* 2012, 61(4); 705 – 7011.
- 10) Bellmunt J, Theodore C, Demkov T, et al. Phase III trial of vinflunine plus best supportive care compared with best supportive care alone after a platinum containing regimen in patients with advanced transitional cell carcinoma of the urothelial tract. *J ClinOncol.* 2009;27(27):4454–4461.
- 11) Plimack ER, Bellmunt J, Gupta S, et al. Safety and activity of pembrolizumab in patients with locally advanced or metastatic urothelial cancer (KEYNOTE-012): a non-randomised, open-label, phase 1b study. *Lancet Oncol* 2017;18:212-220.
- 12) Bellmunt J, de Wit R, Vaughn DJ, et al. Pembrolizumab as second line therapy for advanced urothelial carcinoma. *N Engl J Med.* 2017;376(11):1015-1026.
- 13) Rosenberg JE, Hoffman-Censits J, Powles T, et al. Atezolizumab in patients with locally advanced and metastatic urothelial carcinoma who have progressed following treatment with platinum-based chemotherapy: a single-arm, multicentre, phase 2 trial. *Lancet.* 2016;387(10031):1909-1920.

- 14) Sharma P, Retz M, Siefker-Radtke A, et al. Nivolumab in metastatic urothelial carcinoma after platinum therapy (CheckMate 275): a multicentre, single-arm, phase 2 trial. *Lancet Oncol.* 2017;18(3):312-322.
- 15) Powles T, O'Donnell PH, Massard C, et al. Updated efficacy and tolerability of durvalumab in locally advanced or metastatic urothelial carcinoma [abstract]. *J Clin Oncol* 2017;35 (suppl 6S; abstract 286).
- 16) Apolo AB, Infante JR, Balmanoukian A, et al. Avelumab, an AntiProgrammed Death-Ligand 1 Antibody, In Patients With Refractory Metastatic Urothelial Carcinoma: Results From a Multicenter, Phase Ib Study. *J Clin Oncol.* 2017;35(19):2117-2124.